

# Resin Infiltration Technique: A Case Report of Minimally Invasive Treatment of White Spot Lesions

Lee, Tina M.; Blatz, Markus B.  
University of Pennsylvania School of Dental Medicine

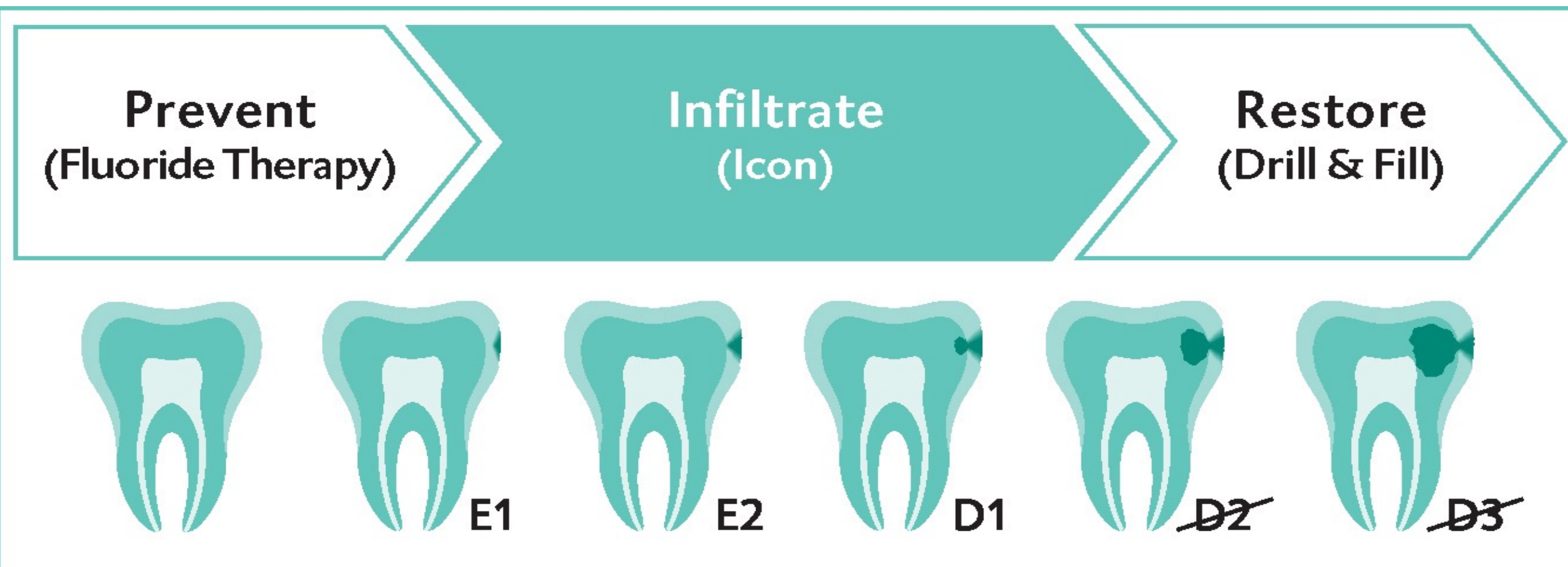


## INTRODUCTION

White spot lesions are sub-surface demineralized enamel caused by a variety of factors including plaque accumulation, post-orthodontic treatment, fluorosis, and hypomineralization. These white opacities when present in the smile line can pose an esthetic concern for many patients. Resin infiltration (Icon®) is a modern, minimally invasive technique aimed to diminish the appearance of white spot lesions and treat initial caries.

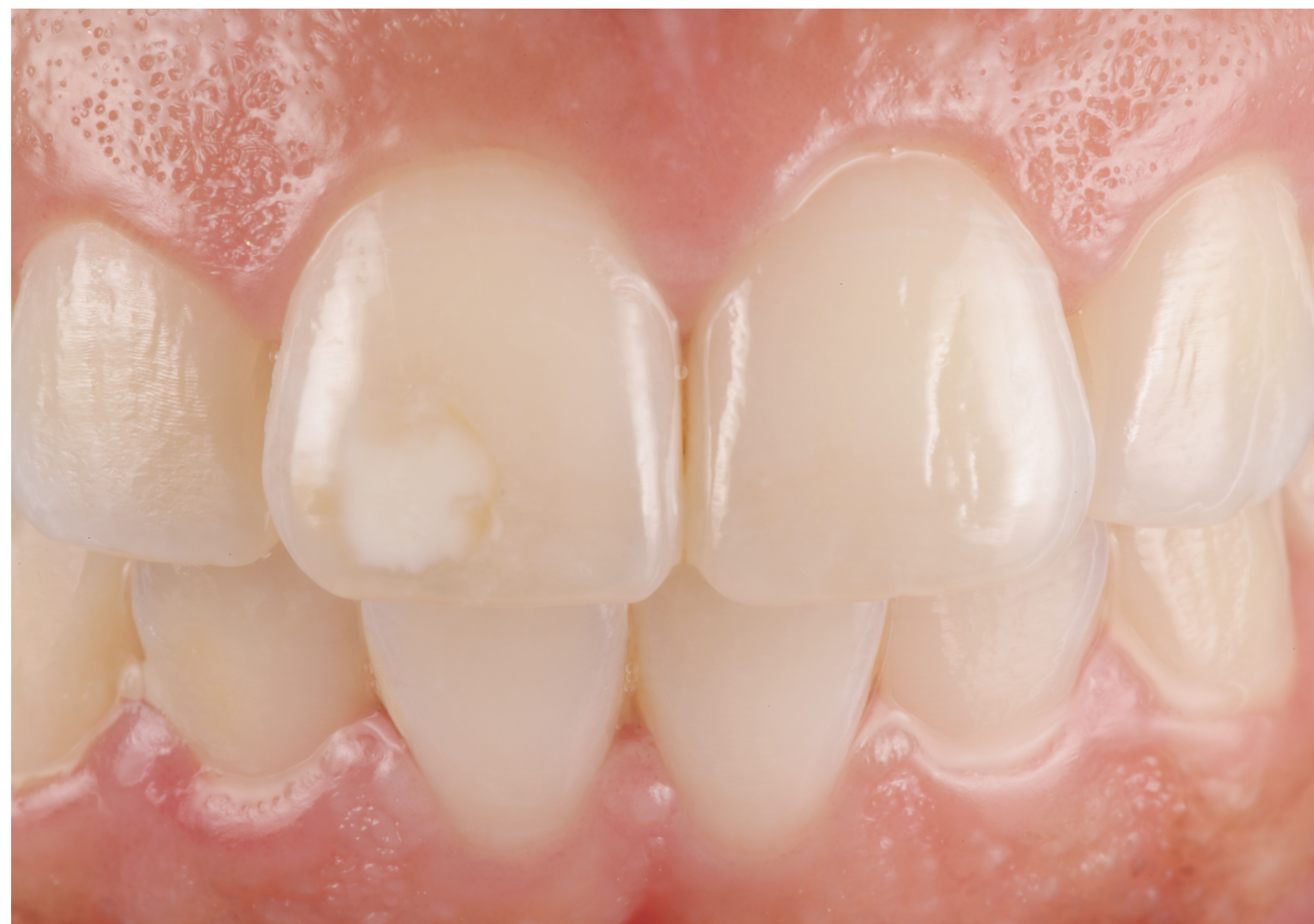

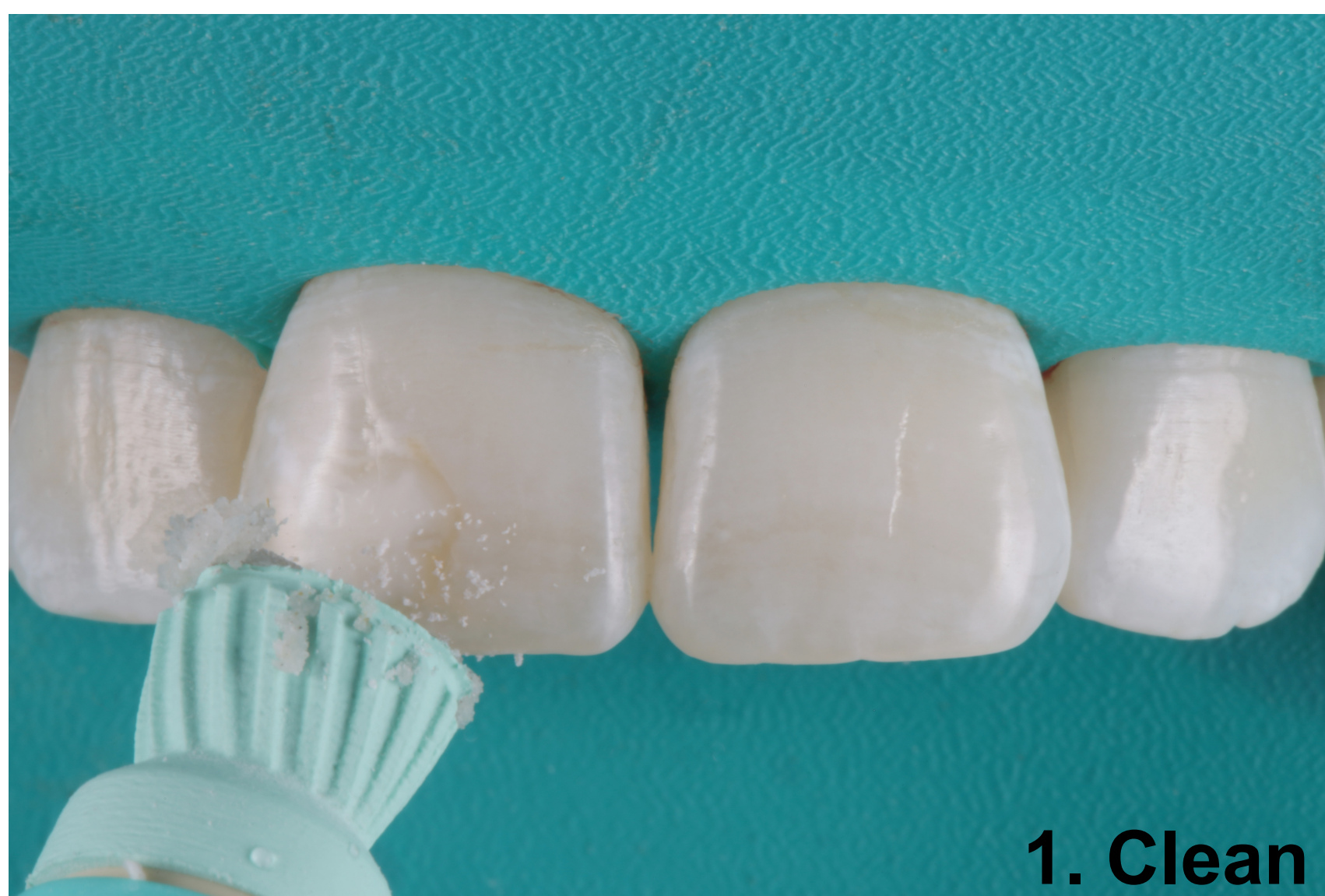Figure 1: 43 year-old female patient presents to Penn Dental Medicine with an asymmetrical white spot lesion on the mid-incisal third of #8 facial surface.

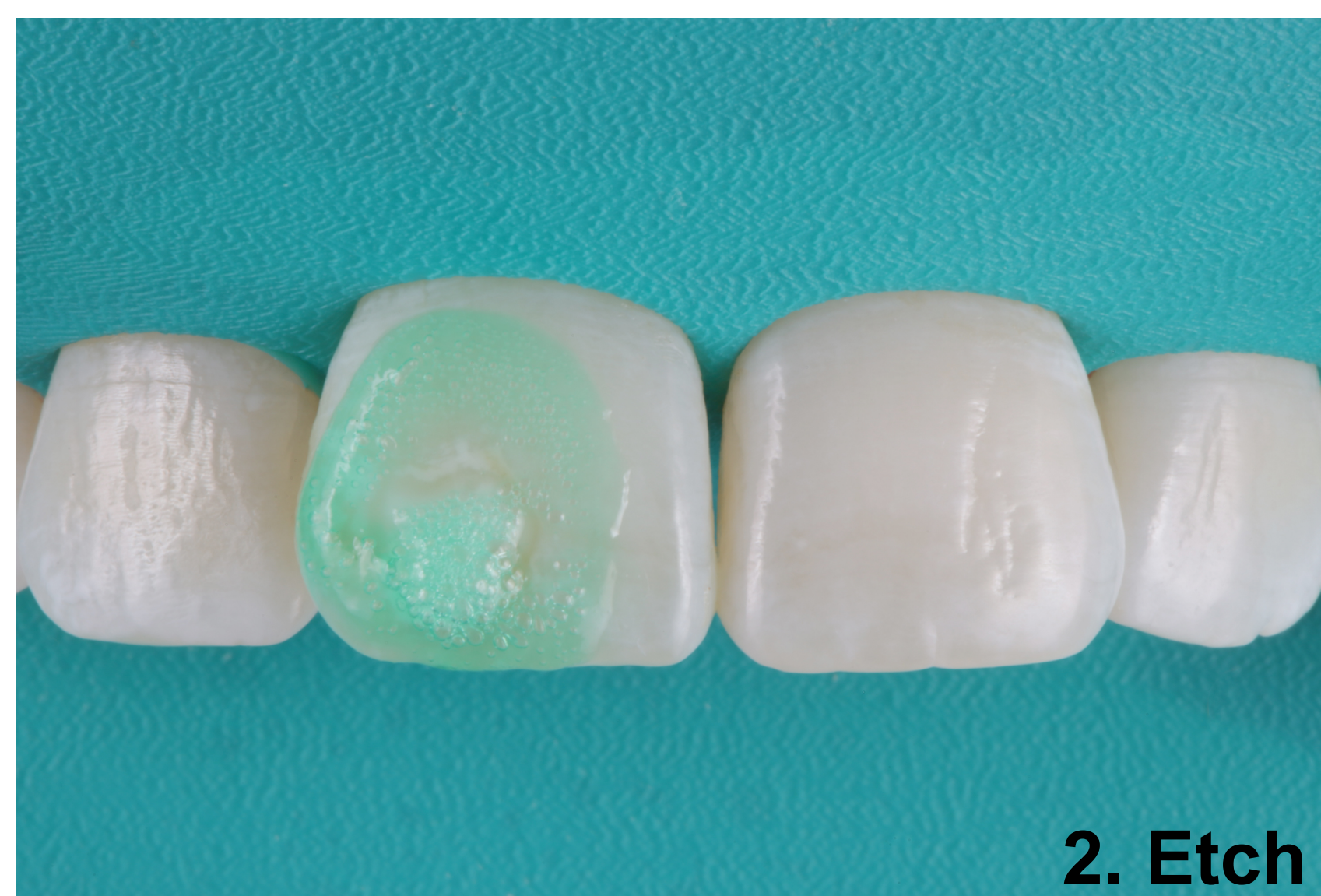

## METHODS AND MATERIAL

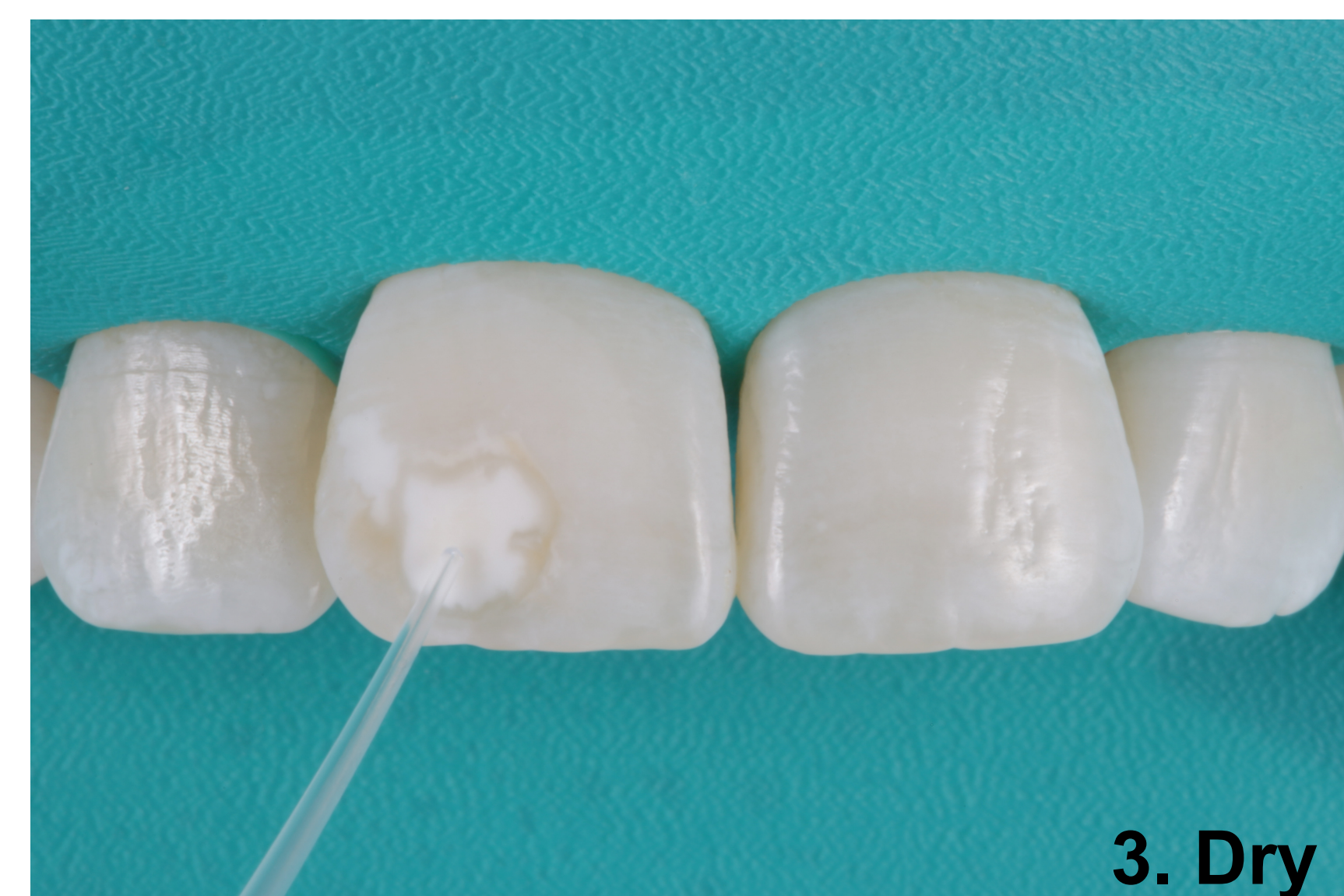Lesion treated via resin infiltration technique following manufacture instructions: etch with 15% hydrochloric acid gel, dry with ethanol, infiltrate with provided resin. Photographic records taken before and immediately after treatment.



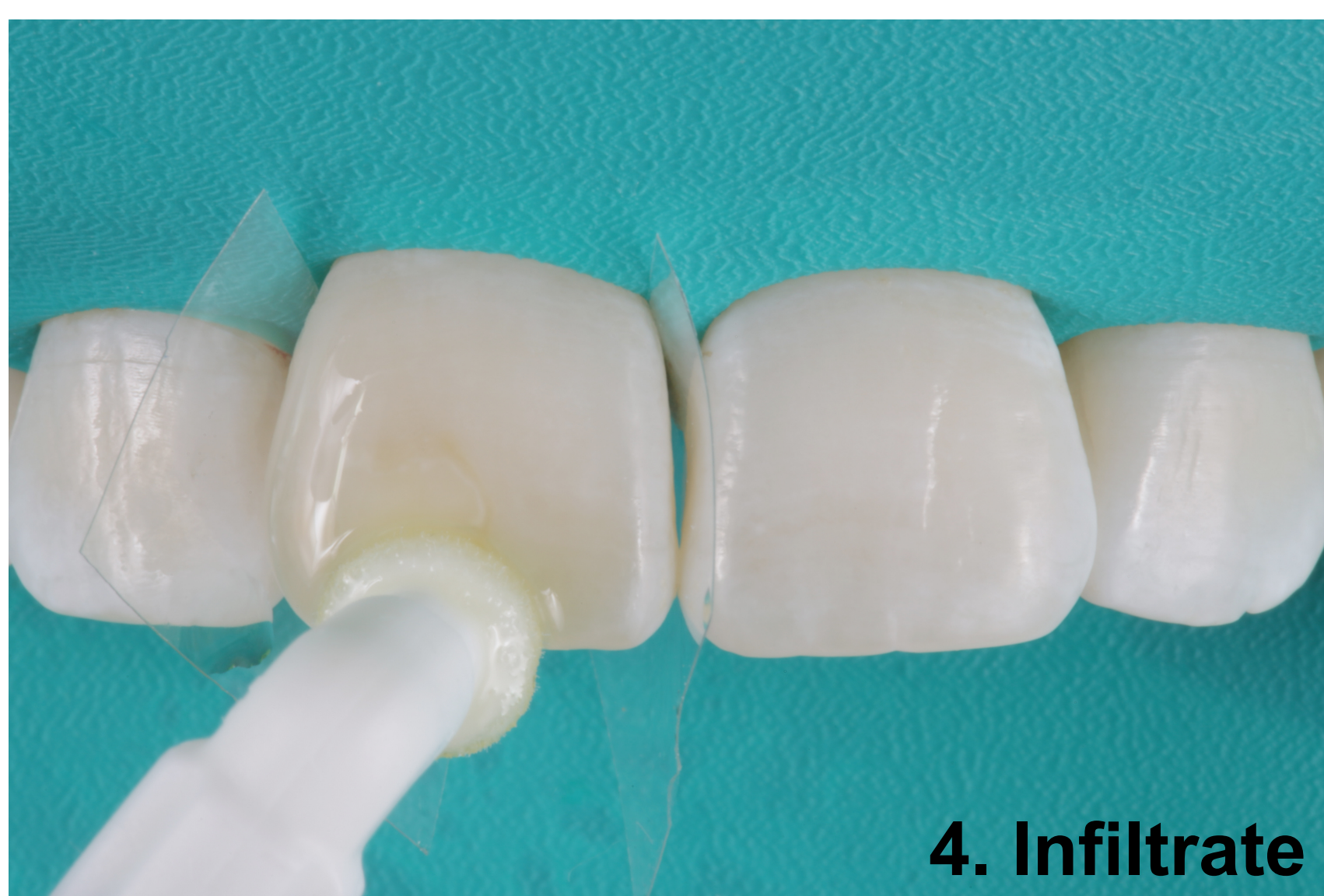1. Clean



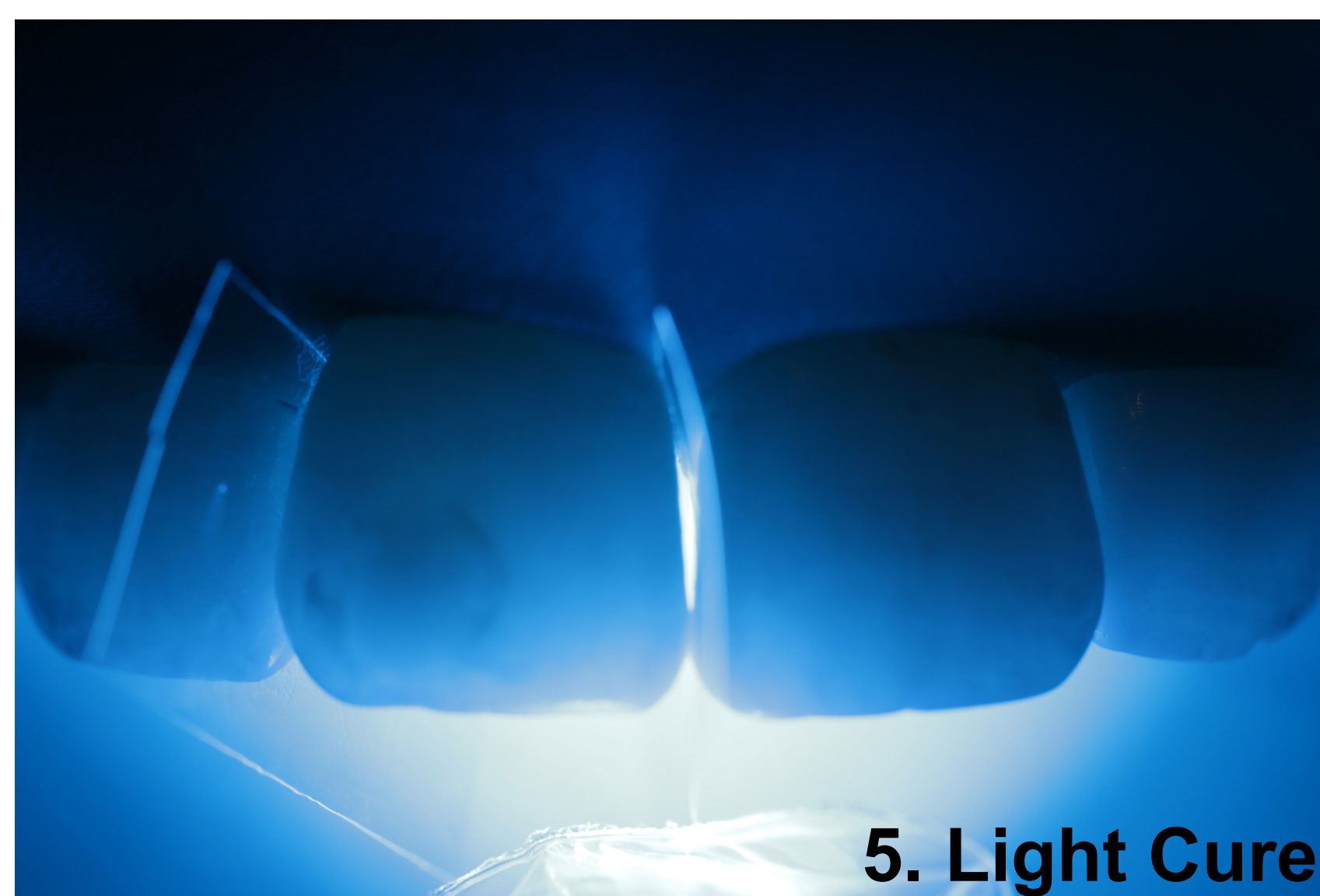
2. Etch



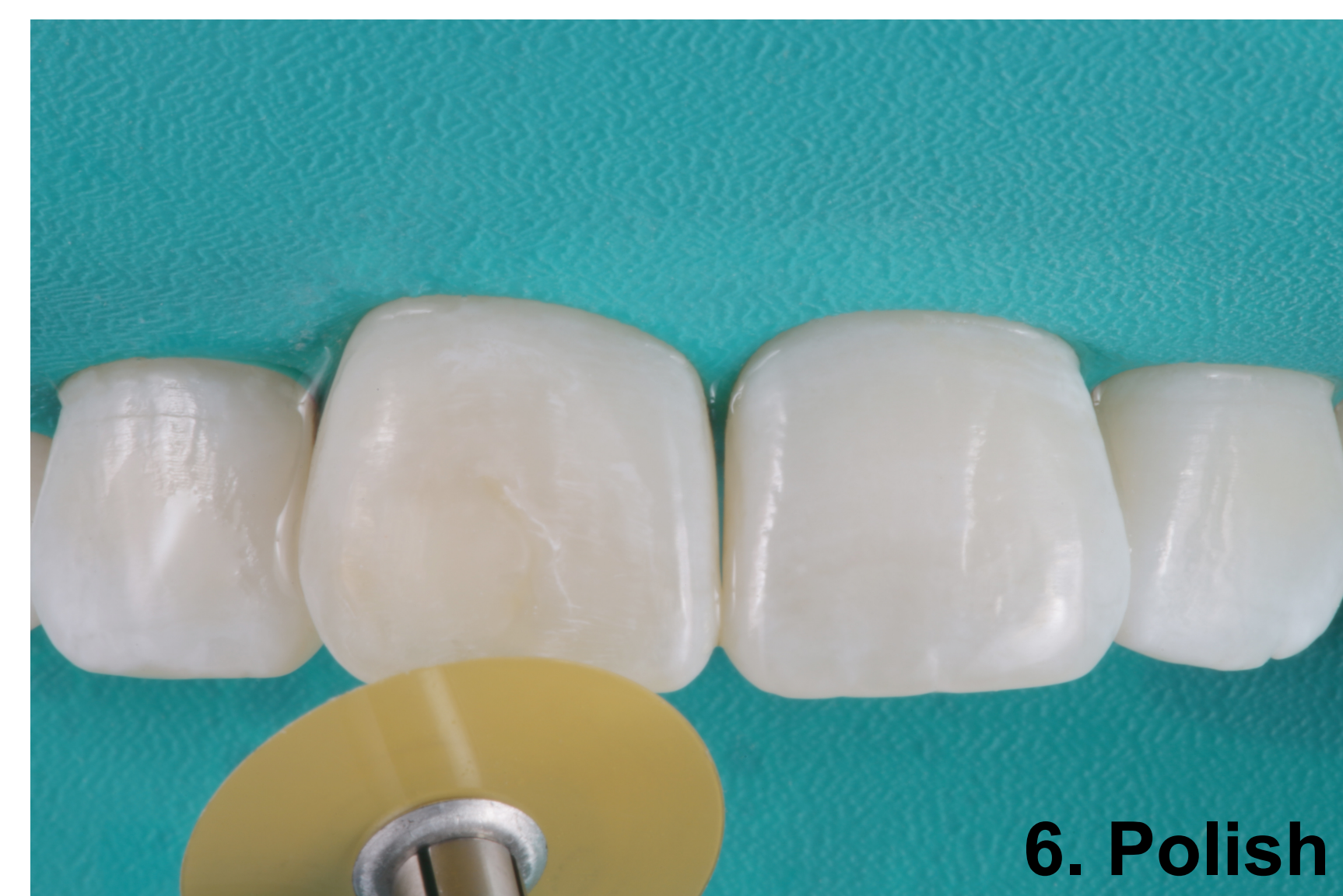
3. Dry



4. Infiltrate



5. Light Cure



6. Polish

## RESULTS AND CONCLUSION

The white spot lesion showed significant reduction in appearance after treatment with resin infiltration. However, the spot was not entirely masked and the border of the original lesion can still be seen. The technique can be an effective treatment option for patients with white spot lesions. However, it is limited to shallow areas of demineralization to allow for full penetration of the infiltrant. Thus, adequate case selection is necessary for success.

Resin infiltration provides a conservative alternative to treating white spot lesions in the esthetic zone. Additionally, the technique can be used to arrest initial caries while preserving healthy tooth structure. Resin infiltration allows for immediate results with reduced chairside time and less patient discomfort compared to traditional methods of treatment.

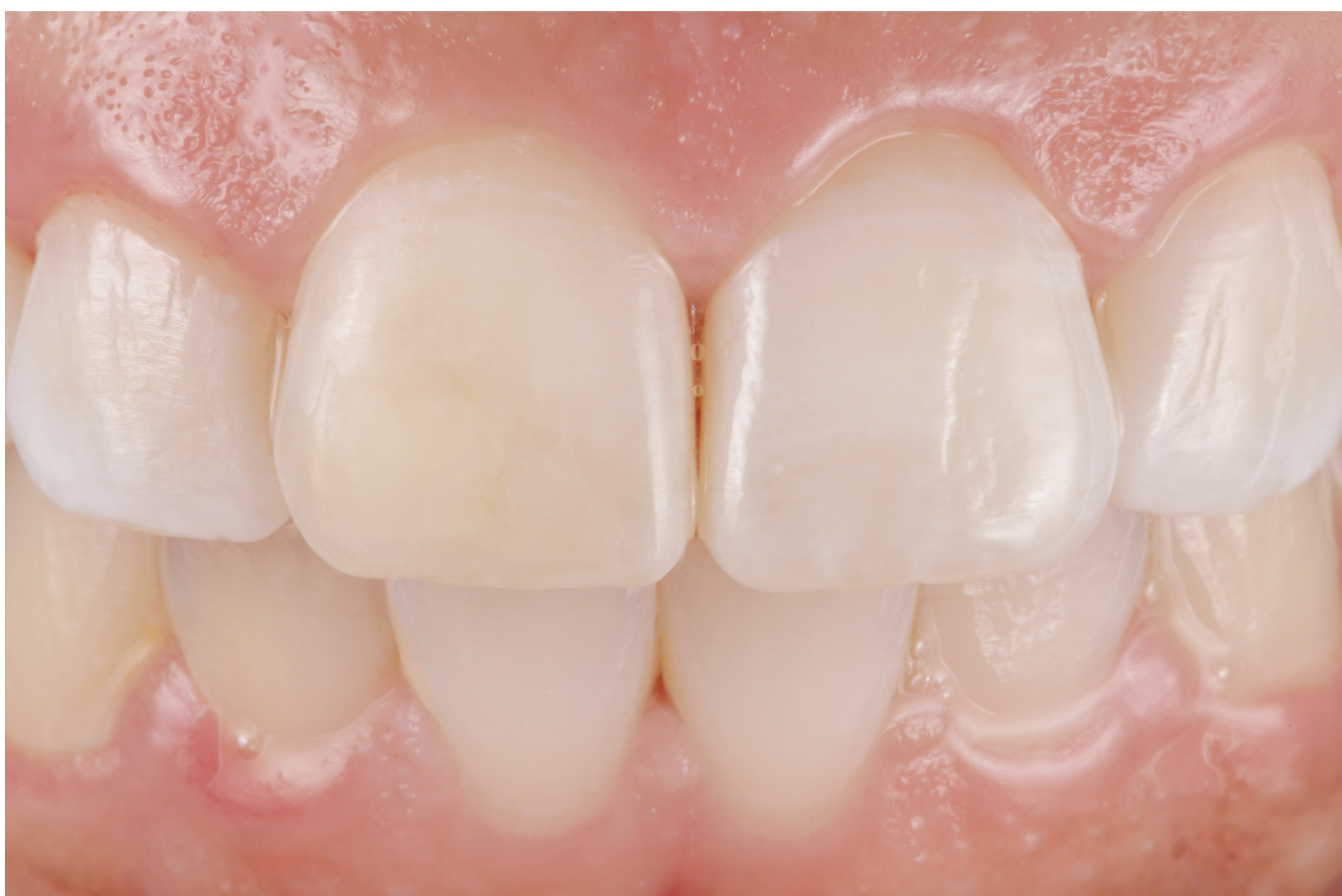

Figure 2: Presentation of patient's #8 white spot lesion immediately after treatment using the resin infiltration technique.